



This article appeared in a journal published by Elsevier. The attached copy is furnished to the author for internal non-commercial research and education use, including for instruction at the authors institution and sharing with colleagues.

Other uses, including reproduction and distribution, or selling or licensing copies, or posting to personal, institutional or third party websites are prohibited.

In most cases authors are permitted to post their version of the article (e.g. in Word or Tex form) to their personal website or institutional repository. Authors requiring further information regarding Elsevier's archiving and manuscript policies are encouraged to visit:

<http://www.elsevier.com/authorsrights>



Contents lists available at ScienceDirect

## Journal of the World Federation of Orthodontists

journal homepage: [www.jwfo.org](http://www.jwfo.org)

## Case Report

## Class II treatment with the Runner in adolescent patients: Combining Twin Block efficiency with aligner aesthetics

Angela Arreghini<sup>a,\*</sup>, Ilaria Carletti<sup>b</sup>, Maria Cristina Ceccarelli<sup>b</sup>, Luca Lombardo<sup>c</sup>, Giuseppe Siciliani<sup>d</sup><sup>a</sup> Assistant Researcher, Postgraduate School of Orthodontics, University of Ferrara, Ferrara, Italy<sup>b</sup> Resident, Postgraduate School of Orthodontics, University of Ferrara, Ferrara, Italy<sup>c</sup> Assistant Professor, Postgraduate School of Orthodontics, University of Ferrara, Ferrara, Italy<sup>d</sup> Professor and Chair, Postgraduate School of Orthodontics, University of Ferrara, Ferrara, Italy

## ARTICLE INFO

## Article history:

Received 2 December 2013

Accepted 4 February 2014

Available online 18 April 2014

## Keywords:

Clear aligners

Functional appliance

Runner

Twin Block

## ABSTRACT

**Background:** This case report describes the treatment of an 11-year-old boy with hypodivergent skeletal Class II, complete molar and canine Class II on the right and edge-to-edge relationship on the left, centered midlines, deep bite, and large over jet.

**Methods:** The patient was treated with a Runner appliance, a series of clear aligners with embedded resin blocks that advance the mandible. This functional appliance was designed on the basis of the construction bite provided by the orthodontist and enables simultaneous incisor alignment to be achieved thanks to pre-programming during the digital setup.

**Results:** After 12 months of treatment, executed by means of six pairs of aligners, the skeletal Class II was reduced, bilateral molar and canine Class I had been achieved, the bite had been opened, the over jet reduced, and the centered midlines preserved. The patient's profile was improved, the upper and lower incisors were well aligned, and adequate expansion had been achieved in the upper lateral sectors, as planned during setup. This result was made possible by the full compliance of the patient, who, thanks to the aesthetics and streamlined design of the Runner aligners, wore them for 22 h/day throughout the entire course of treatment.

**Conclusions:** In this case, the Runner appliance was used with success for correcting Class II malocclusion in a young patient, with improvements in the patient's profile, alignment of the upper and lower incisors, and adequate expansion in the upper lateral sectors.

© 2014 World Federation of Orthodontists.

## 1. Introduction

Resolving Class II cases in growing patients by means of functional appliances has always represented a challenge for the orthodontist. Although the efficacy of appliances such as the Twin Block, Bionator, and Frankel II has been well-documented [1], these devices do have a limitation, namely, patient compliance. Indeed, to achieve the results reported in the literature, compliance has to be absolute, which, unfortunately, cannot be guaranteed in practice. This is particularly true with devices such as these, which are bulky, highly visible, and can have a marked impact on speech. All of these features make it difficult to obtain full compliance, particularly from children and teenagers [2]. In fact, a noncompliance rate of 18% has been

demonstrated in children and rises to 30% in adolescence [3], a time of growth spurt and therefore the optimum period for orthodontic treatment. In other words, one in three teenage patients do not wear their functional appliances for a sufficient number of hours.


Another drawback of conventional functional appliances is that they are unable to provide precise dental movements. This means that alignment must be performed by fixed appliances during an additional phase of treatment.

It used to be thought that children were not sensitive to the visibility of orthodontic appliances. However, it has been demonstrated that even infants possess aesthetic sensibilities and are well aware of what is attractive and what is not. Indeed, children as young as 5 years can distinguish between two types of smile, and from 8 years of age, the aesthetic criteria of children are, for all intents and purposes, identical to those of adults [4].

Of all the different types of appliance on the market, clear aligners seem to be the most appreciated, even in young patients, thanks to their low aesthetic impact. However, aligners are not

\* Corresponding author: Postgraduate School of Orthodontics of Ferrara, Via, Montebello, 31 Ferrara, Italy 44100.

E-mail address: [angela\\_arreghini@yahoo.com](mailto:angela_arreghini@yahoo.com) (A. Arreghini).



**Fig. 1.** Pre-treatment extraoral photographs.

always indicated in growing patients because they perform only dentoalveolar movement, being unable to resolve functional or skeletal issues [5].

To fill this gap, the Runner, a series of clear aligners with incorporated blocks for mandibular advancement, has been developed thanks to the collaboration between the Postgraduate School of Orthodontics of Ferrara (Italy) and the Leone SPA Company (Sesto Fiorentino, Firenze, Italy). The main advantage of the Runner system is that it can achieve incisor alignment while advancing the mandible, thanks to a fully pre-programmable digital setup. This case report details the outcome of treating an 11-year-old hypodivergent skeletal Class II patient with such a device.

## 2. Case report

### 2.1. Diagnosis and etiology

The patient, L.M., an 11-year-old boy, presented with convex profile and excessive incisor exposure at rest (Fig. 1). Intraoral examination revealed complete permanent dentition, with the exception of tooth 47 and the third molars. The molar Class II was complete on the right, and edge-to-edge on the left, and the bilateral canine Class II was more severe on the right. The midlines were centered, but a deep bite (7 mm) and large over jet (8 mm)

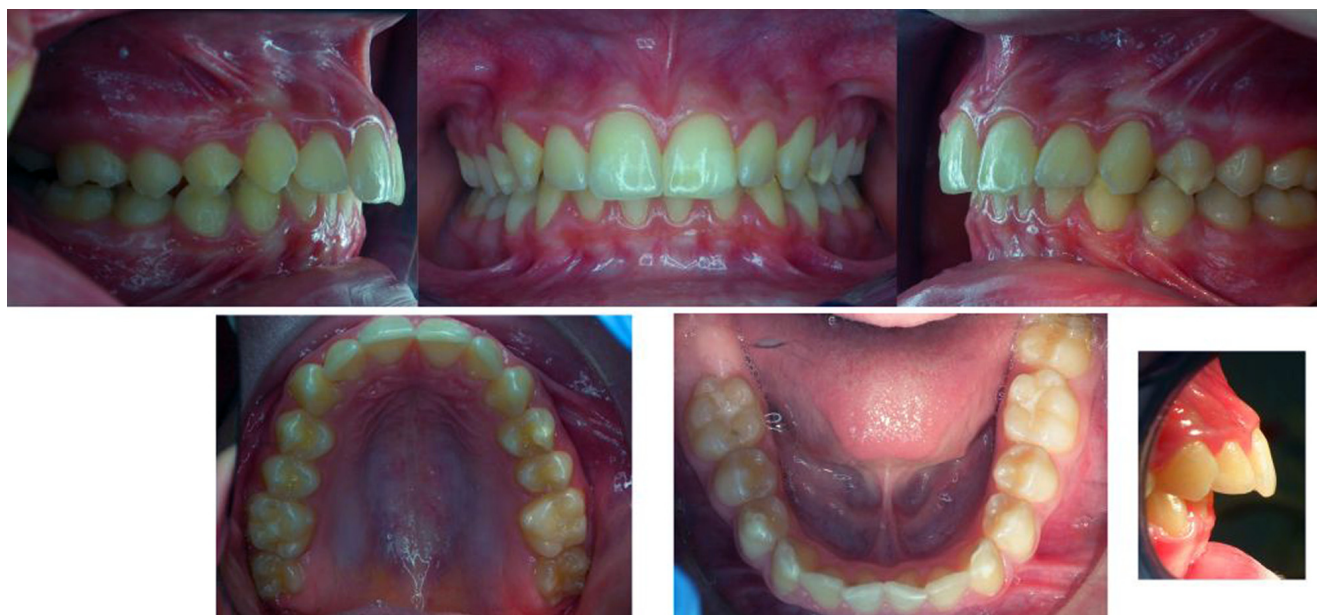were in evidence. The upper and lower incisors were slightly rotated, and the upper jaw was narrow (Figs. 2 and 3). Cephalometric analysis showed hypodivergent skeletal Class II. The lower incisors were proclined (incisor to mandibular plane angle  $97.7^\circ$ ), and the upper incisors retroclined ( $103.6^\circ$  with respect to the bis-pinal plane) (Fig. 4, Table 1). The patient had undergone no previous orthodontic treatment.

Simulation of mandibular advancement resulted in a markedly improved profile (Fig. 5), confirming, as suggested by Clark [6], that the patient was a good candidate for treatment with a functional appliance.

Radiographic analysis of the middle finger revealed that the patient was in the MP3 phase (Fig. 6) according to Hägg and Tanager [7], that is, close to the pubertal growth peak.

### 2.2. Treatment objectives

Because the patient was close to the pubertal growth peak, the primary aim of the treatment was to promote mandibular advancement to correct the Class II and improve the profile. The dental Class II also needed to be corrected, and the over jet reduced, and the bite was to be opened through extrusion of the posterior teeth. All of this needed to be achieved while preserving the centered midlines, aligning the incisors, and achieving slight dentoalveolar expansion in both arches.



**Fig. 2.** Pre-treatment intraoral photographs.

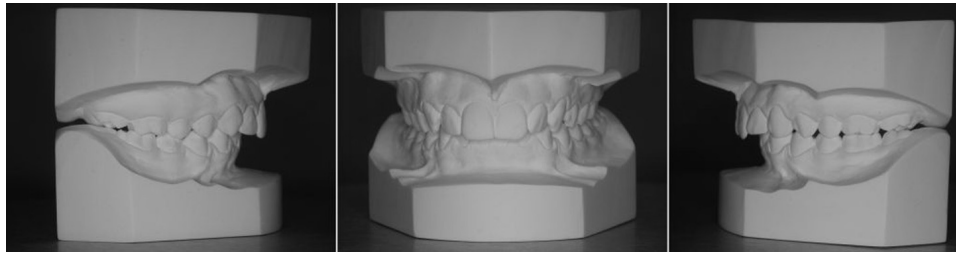


Fig. 3. Pre-treatment dental casts.

### 2.3. Treatment alternatives

Functional treatment of Class II can be effectively achieved in growing patients by means of conventional appliances such as Twin Block or Frankel II. However, these types of devices are limited by their bulkiness, high visibility, and interference with phonation. Although they are very efficacious when worn full-time, compliance in adolescent patients, particularly in male patients, is notoriously difficult to guarantee [8]. In addition to this potential impediment to good treatment outcome, conventional functional appliances are unable to provide precise dentoalveolar movements, which would necessitate further treatment with a fixed appliance.

This led to the choice of using the Runner, a functional appliance designed to overcome the aforementioned limitations. In essence, the Runner is a sequence of clear aligners with reciprocally articulating blocks encased in the resin. These maintain the mandible in an advanced position, based on indications revealed by the construction bite taken by the orthodontist.

To make the Runner, the patient's plaster models are scanned using an optical scanner, first each arch separately and then in occlusion, according to the construction bite provided by the orthodontist (which must not exceed 70% of the patient's maximum protrusion) [9]. Virtual setup software (3Shape, OrthoAnalyzer, Copenhagen, Denmark) is then used to simulate stepwise correction of the malocclusion, in this case anterior (Fig. 7), and the blocks are designed according to the principles on which the original Twin Block is based [6]. In particular, the upper blocks extended from the first molar to the mesial crest of the first premolar, and the lower blocks covered the premolars, leaving the marginal crest distal to the second premolar unencumbered. The height and thickness of the blocks were sufficient to ensure that stable mandibular advancement is maintained, with an anterior disclusion of 2 to 4 mm and a posterior disclusion of 5 to 7 mm, as indicated by the construction bite [9]. The inclination of the plane was roughly 70° (Fig. 8).

After CAD design, the stereolithography files were prototyped in resin by Digital Service (Leone S.p.A., Florence, Italy), and two pairs of blocks were produced for each pair of aligners, each

corresponding to a step in the setup. The aligners were then thermoformed around the blocks, encasing them completely (Fig. 9).

### 2.4. Treatment progress

Six pairs of Runner aligners were produced in this way, each one corresponding to a programmed treatment step. Each pair of Runners was worn for 22 h/day, being removed only for mealtimes and hygiene procedures. Each pair of Runners was replaced with the next in the series after 20 days (Fig. 10).

Starting with the second set of aligners, the upper blocks were progressively milled (Fig. 11) to leave 1 to 2 mm of space for extrusion of the lower molars and correction of the deep bite. The last set of Runners was worn until the over jet had been corrected, giving a total active treatment time of 8 months.

The active phase was followed by a supplementary phase lasting 4 months, during which the Runner was worn nocturnally only, and the lateral blocks were progressively milled to bring about extrusion of the premolars.

### 2.5. Treatment results

After 12 months of functional treatment with the Runner, there was a marked improvement in profile, a lengthening of the lower facial third, and less exposure of the incisors at rest (Fig. 12). Bilateral class I molar and canine relationships had been achieved, and the midlines remained centered. The over jet was markedly reduced, and the bite had been opened. The tooth rotations had been corrected as planned on the digital setup, and the arches had undergone dentoalveolar expansion, promoting dental alignment without recourse to stripping (Fig. 13).

Post-treatment cephalometric analysis revealed that the skeletal class II had been reduced, and the degree of divergence increased (Fig. 14, Table 1). The position of the upper incisors with respect to the bisplanal plane had been reduced to 1.7°, and the lower incisors had been proclined by 7.9° (incisor to mandibular plane angle 105.6°).

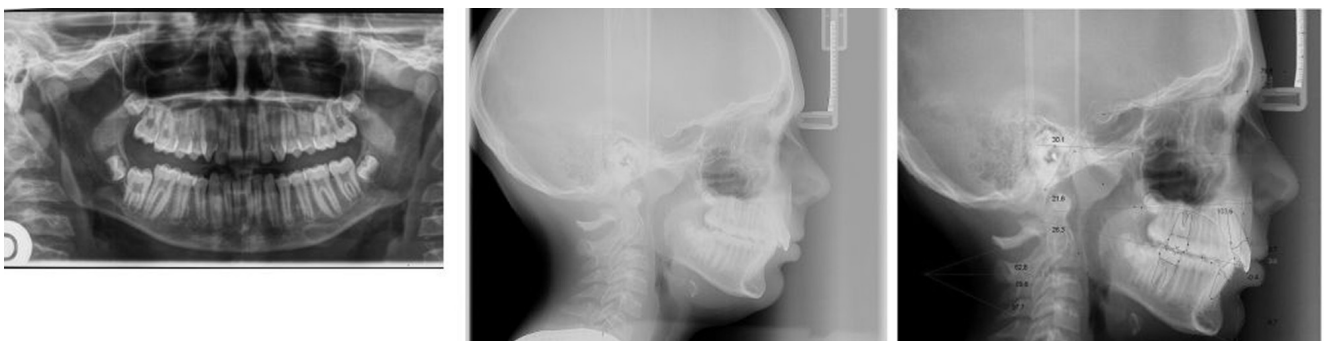

Fig. 4. Pre-treatment x-rays.

**Table 1**  
Cephalometric analysis

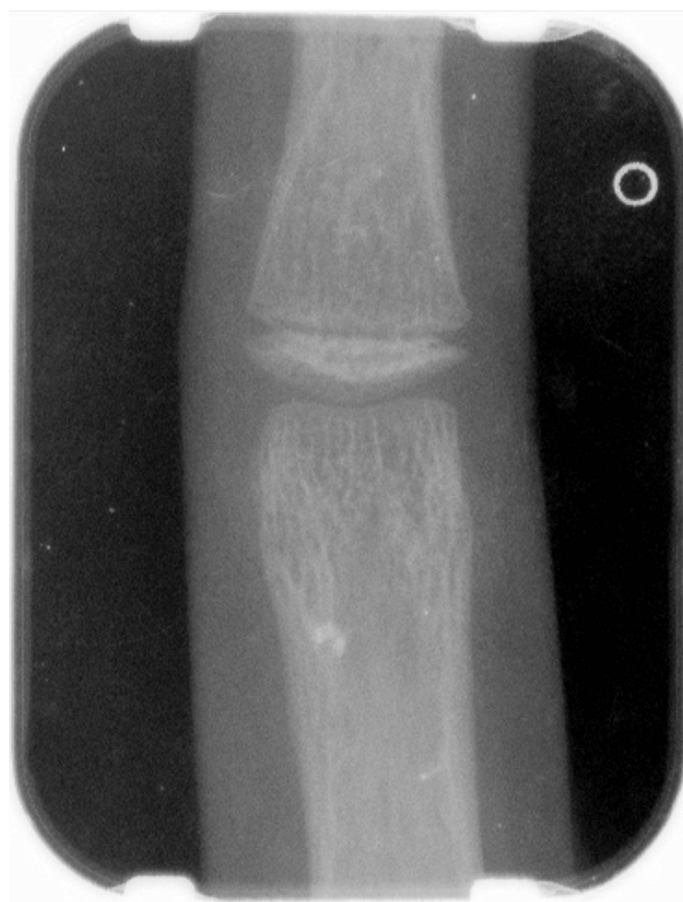Measurement	Initial	Final
SNA (°)	79.8	78.0
SNB (°)	73.6	74.1
ANB (°)	6.3	3.9
Wits appraisal (mm)	3.6	−1.6
FMA (MP-FH) (°)	21.6	24.4
MP-SN (°)	32.5	34.1
Palatal-mandibular angle (°)	26.3	27.1
Palatal-occipital plane (°)	13.6	16.7
Mandibular plane to occipital plane (°)	12.7	10.4
U-incisor protrusion (U1-APo) (mm)	6.6	5.3
L1 protrusion (L1-APo) (mm)	−0.4	3.2
U1 - palatal plane (°)	103.6	101.9
U1 - occipital plane (°)	62.8	61.4
L1 - occipital plane (°)	69.6	64.0
IMPA (°)	97.7	105.6

ANB, point A, nasion, point B angle; APo, point A-Pogonion line; FH, Frankfort horizontal plane; FMA, Frankfort mandibular plane angle; IMPA, incisor to mandibular plane angle; L1, central lower incisor; MP, mandibular plane; SN, sella-nasion line; SNA, sella, nasion, point A angle; SNB, sella, nasion, point B angle; U1, upper central incisor.

### 3. Discussion

Functional treatment of growing Class II patients during their pubertal growth spurt can bring about significant skeletal and dentoalveolar modifications. According to the review by Cozza et al. [1], the Twin Block is the most efficient removable functional appliance, as it can stimulate 0.23 mm/month of mandibular growth (for a total of 3.4 mm in 13 months), followed by the Bionator (0.17 mm/month, total 2.8 mm in 12 months), and then the Frankel II (0.09 mm/month, total 2.8 mm in 18 months). The mechanism behind the Clark Twin Block is based on the presence of an inclined plane, which pushes the mandible forward, liberates the arches, and redirects the occlusal forces to drive the mandibular advancement and arrest maxillary growth [6]. In clinical investigations, the efficacy of the Twin Block has only been exceeded by the Herbst appliance, which, being fixed, does not require compliance. However, the Twin Block is less likely to break, and is therefore more convenient for both the patient and the orthodontist to handle [10].

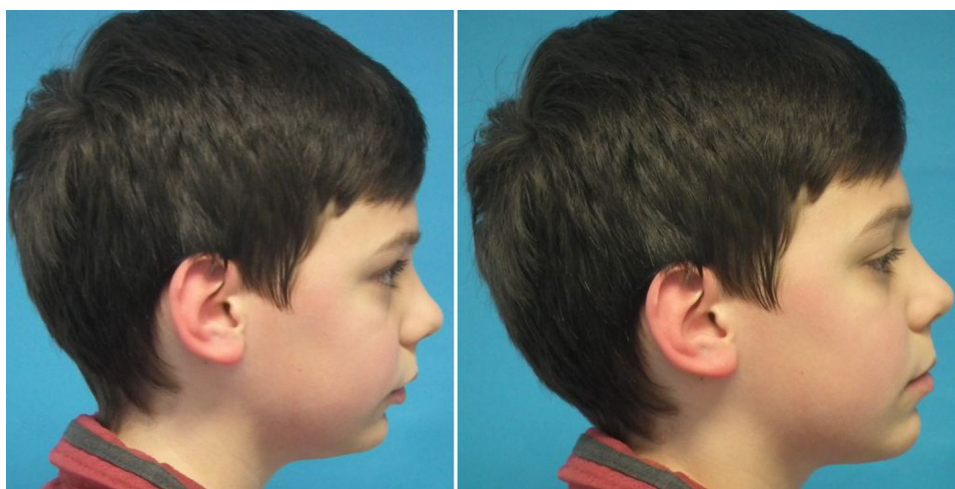Nonetheless, compliance is a major limiting factor of this device, which, however, the Runner is able to overcome. This functional appliance marries the efficiency of the Twin Block and the aesthetics and low bulk of clear aligners. This enables compliance to be maximized because the appliance can be worn full-time without



**Fig. 6.** X-ray of middle finger.

unsightliness or altered phonation (Fig. 15). Furthermore, using the digital setup, it is possible to plan simultaneous alignment of the incisors, thereby eliminating the additional phase required by fixed multibracket devices.

As seen in this case report, the effects of the Runner are visible at both skeletal and dentoalveolar levels, and are comparable to those seen after full-time use of Clark Twin Block. A prospective study by Lund and Sandler [11] revealed that the Twin Block can reduce the point A, nasion, point B angle by roughly 2°, retrocline the incisors



**Fig. 5.** Simulation of mandibular advancement: profile is improved.

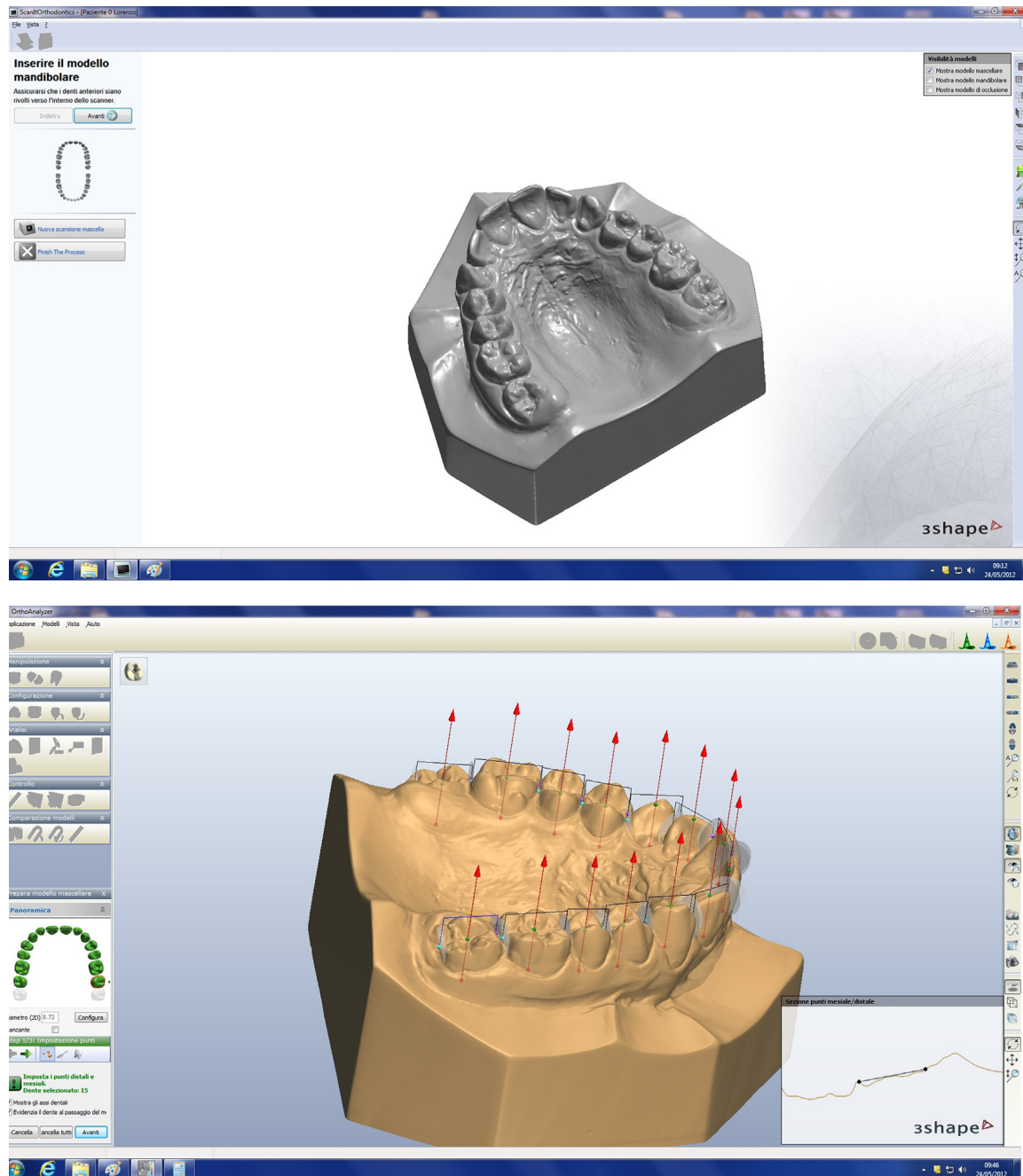


Fig. 7. Digitalization of models and virtual setup.

by up to 10°, and increase the incisor to mandibular plane angle by 8° on average. Greater skeletal effects can be achieved if the treatment is performed during the pubertal growth spurt, and, like the Twin Block, the Runner acts on both mandibular and maxillary components of the occlusion.

#### 4. Conclusions

This case report highlights the innovative nature of the Runner, which has been designed specifically to meet the functional and aesthetic demands of today's teenagers. It is able to correct Class II malocclusion in young patients according to the principles of the Clark Twin Block, and its design increases the likelihood of full-time compliance by not compromising social interaction. Indeed, the device is transparent and lightweight and does not impede normal

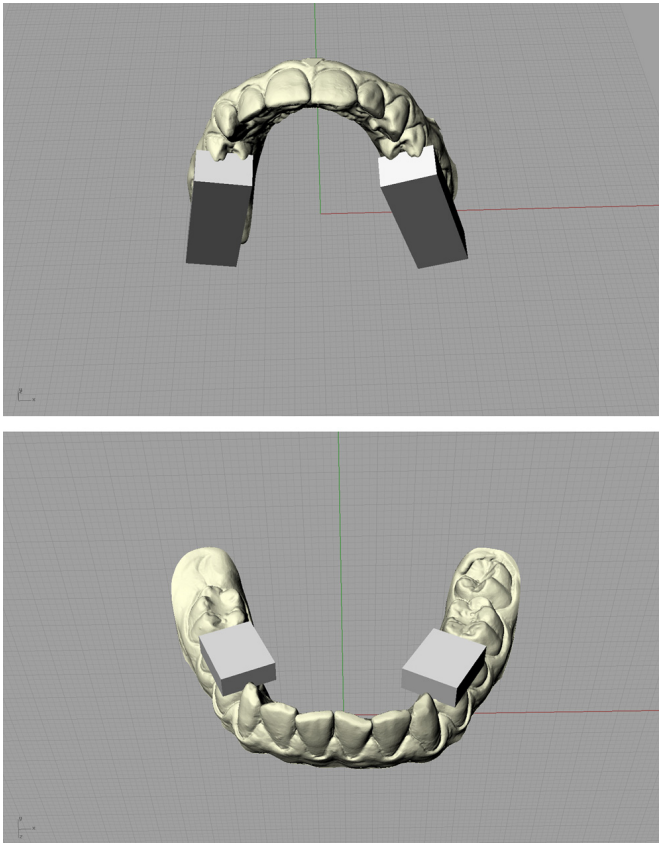
speech. The Runner is also able to align the incisors while advancing the mandible, thereby providing the orthodontist with a useful tool for all-round functional and dentoalveolar treatment.

#### Acknowledgment

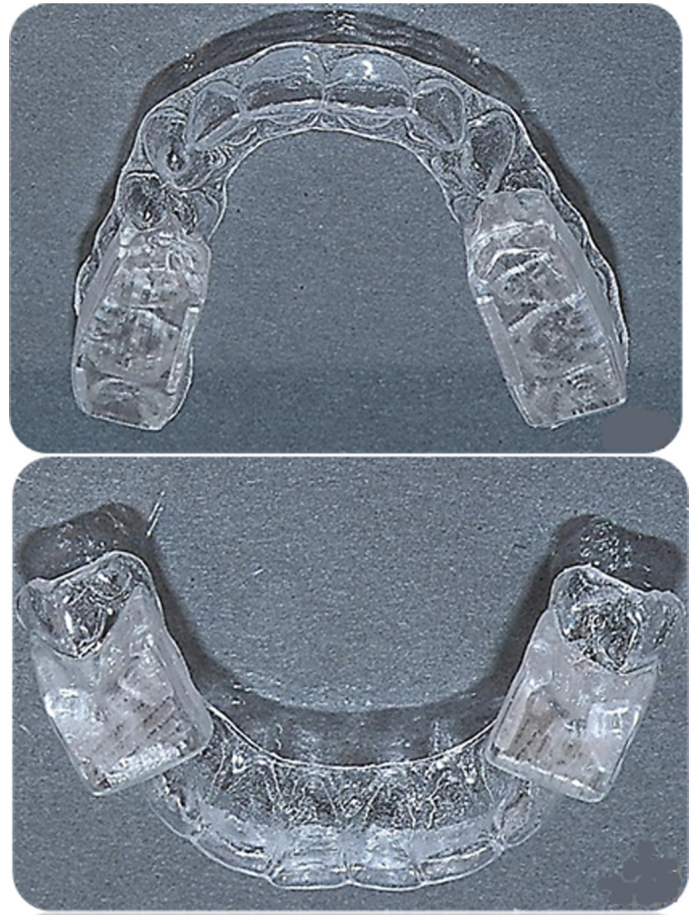
We would like to acknowledge the Leone SPA Company for the collaboration in the ideation and the development of the appliance.

#### References

- [1] Cozza P, Baccetti T, Franchi L, De Toffol L, McNamara Jr JA. Mandibular changes produced by functional appliances in class two malocclusion: a systematic review. *Am J Orthod Dentofacial Orthop* 2006;129:599.e1–599.e12.
- [2] Ackerman MB, Thornton B. Posttreatment compliance with removable maxillary retention in a teenage population: a short-term randomized clinical trial. *Orthodontics (Chic)* 2011;12:22–7.



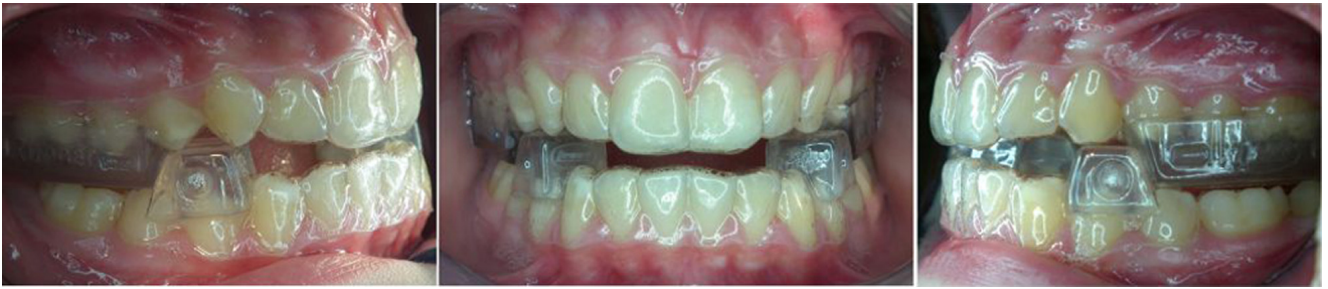**Fig. 8.** Designing the Runner.



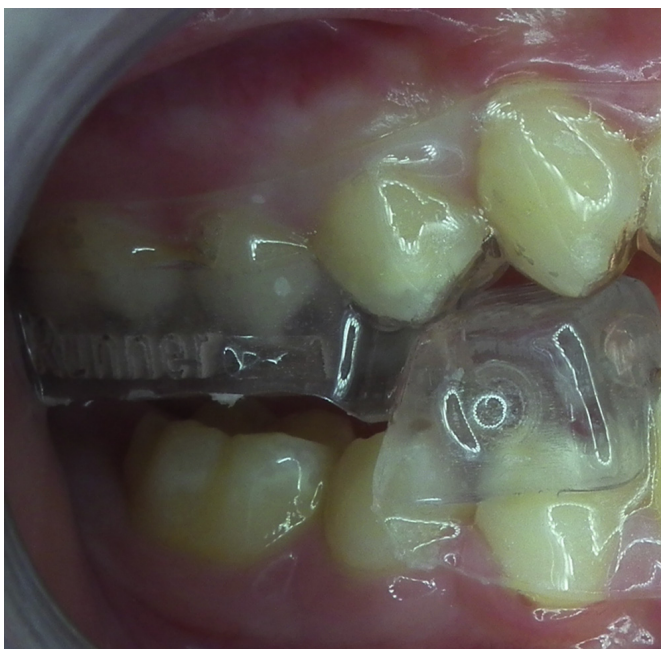**Fig. 9.** The Runner.

- [3] O'Brien K, Wright J, Conboy F, et al. Early treatment for Class II Division 1 malocclusion with the Twin-block appliance: a multi-center, randomized, controlled trial. *Am J Orthod Dentofacial Orthop* 2009;135:573–9.
- [4] Duchenne GB. The mechanism of human facial expression. Cambridge, UK: Cambridge University Press; 1990.
- [5] Walton DK, Fields HW, Johnston WM, et al. Orthodontic appliance preferences of children and adolescents. *Am J Orthod Dentofacial Orthop* 2010;138: 698.e1–698.e12.
- [6] Clark WJ. Twin Block functional therapy: applications in dentofacial orthopaedics. 2nd ed. St. Louis: Mosby; 2002.
- [7] Hägg U, Taranger J. Skeletal stages of the hand and wrist as indicators of the pubertal growth spurt. *Acta Odontol Scand* 1980;38:187–200.
- [8] Southard KA, Tolley EA, Arheart KL, Hackett-Renner CA, Southard TE. Application of the Millon adolescent personality inventory in evaluating

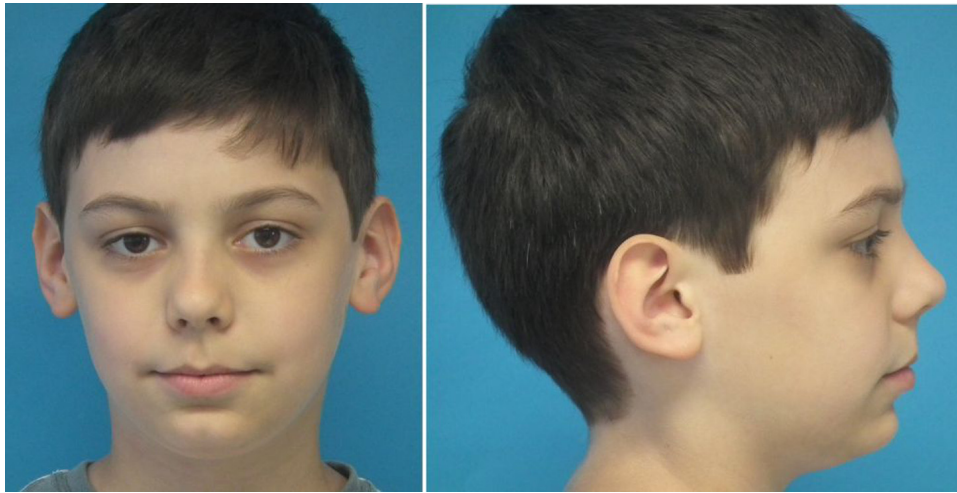
- orthodontic compliance. *Am J Orthod Dentofacial Orthop* 1991;100: 553–61.
- [9] Banks P, Wright J, O'Brien K. Incremental versus maximum bite advancement during Twin Block therapy: a randomized controlled clinical trial. *Am J Orthod Dentofacial Orthop* 2004;126:583–8.
- [10] O'Brien K, Wright J, Conboy F, et al. Effectiveness of treatment for class II malocclusion with the Herbst or Twin Block appliances: a randomized, controlled trial. *Am J Orthod Dentofacial Orthop* 2003;124:128–37.
- [11] Lund DI, Sandler PJ. The effects of Twin Blocks: a prospective controlled study. *Am J Orthod Dentofacial Orthop* 1998;113:104–10.



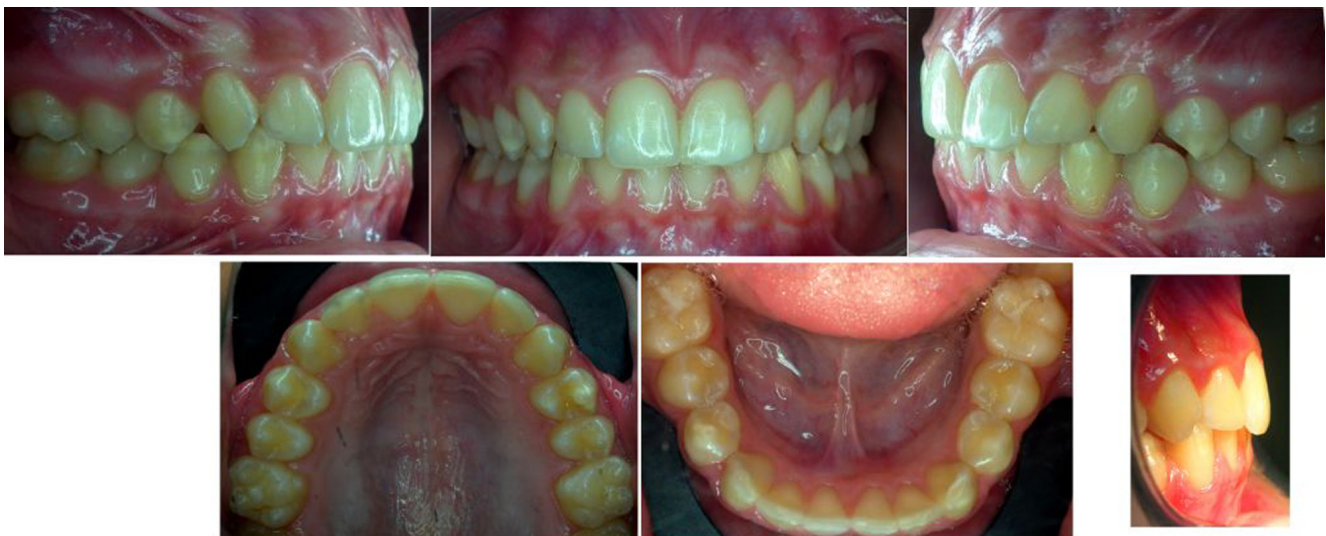**Fig. 10.** The Runner in place.



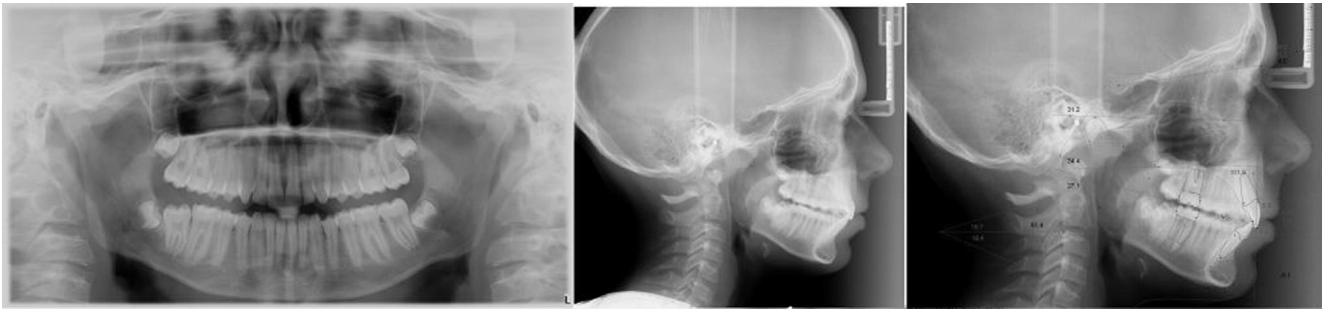**Fig. 11.** Progressive milling of the upper block to enable molar extrusion.



**Fig. 12.** Post-treatment extraoral photographs.



**Fig. 13.** Post-treatment intraoral photographs.



**Fig. 14.** Post-treatment x-rays.



**Fig. 15.** Minimal visibility of Runner when worn.